



**PATIENT**

Vivian Burrows

**SPECIES**

Feline

**BREED**

DSH

**SEX**

Female Spayed

**AGE**

20 years

**WEIGHT**

9.5

**INTERPRETED BY**

Maggie Machen Lamy,  
DVM, DACVIM  
(Cardiology)

**IMAGING PERFORMED BY**

Sang K Han, DVM

**HOSPITAL NAME**

Oso Pet Care Center

**REFERRING VET**

Dr. Han

**INVOICE**

22589

**DATE**

2/15/22

**PRESENTING CLINICAL SIGNS**

History: The patient has a UTI; has not been using the litterbox and isn't defecating correctly. Appetite lower than normal. Hyperthyroid (1/4tab 5mg BID) with suspected vestibular that was treated with meclizine renal disease (twice week sc fluid)

-Abnormal PE/Chem/CBC/UA Results: Arrhythmia on heart auscultation.

**ECHOCARDIOGRAM FINDINGS**

2D, m-mode, color flow and doppler imaging is available. The left ventricular wall is irregular with apical thinning. No significant hypertrophy. There is a diffusely hyperechoic endocardium consistent with mild fibrosis. The endocardium also appears remodeled. The papillary muscles are asymmetric and hyperechoic. The left atrium is normal in size. The right atrium is normal in size. The right ventricle appears normal. The mitral valve is normal in structure and mobility. No obvious valve regurgitation. Blood flow through the RVOT is normal in velocity. No pleural or pericardial effusion seen. No obvious cardiac tumors.

**CARDIAC CHART**

FELINE CARDIAC PARAMETERS	BODY WEIGHT	HR (BPM)	IVSd (cm) (Moise, Pipers)	LVIDd (cm) (Moise, Pipers)	LWVd (cm) (Moise, Pipers)	FS (%)	EF (%)
NORMAL PARAMETER	-----	150-240	0.35-0.55	<2 (mean 1.5)	3.5-0.55	35-67	80-100
PATIENT	9.5	NM	0.38	1.7	0.42	59	90
FELINE CARDIAC PARAMETERS	LA/AO (Boon)	LA/AO HEART BASE (Swe) (Abbott)	LA 2D short axis Base view (cm) (Abbott)		LVOT VEL (m/s)	RVOT VEL (m/s)	E max (m/s)
NORMAL	<1.5	<1.3	<1.2		<1.6	<1.3	<0.9
PATIENT	NM	1.0	1.1		NM	0.95	NM

*\*Note: All measurements based upon multi-modal images and methods. An average value is reported.*  
Adapted from June Boon, Veterinary Echocardiography, 1998  
Abbott J & MacLean H JVIM 2006;20: 111-119, Moise et al. Am J Vet Res 47:1476, 1986. Pipers et al. Am J Vet Res 40:882, 1979.

**INTERPRETATION OF THE FINDINGS & FURTHER RECOMMENDATIONS**

Overtly normal geriatric cardiac structure and function. The LV wall thickness is irregular with apical thinning, which is likely an age-related change. Early restrictive or unclassified disease is certainly not ruled out prior to assessing for progression. There is diffuse remodeling and fibrosis of the LV wall which should be monitored going forward. The LA is normal indicating risk for complication is low at this time.

Given these findings, no medications are indicated. In a geriatric cat, an arrhythmia could be due to mild structural changes seen here (unlikely) or systemic illness and both are considered possible. Highly recommend a six-lead ECG for further evaluation. Bradycardia is noted throughout the study and AV block is a possibility.

No structural contraindication for general anesthesia; however, the arrhythmia should certainly be further evaluated, IV fluid restriction, etc.



**PATIENT**

Vivian Burrows

**SPECIES**

Feline

**BREED**

DSH

**SEX**

Female Spayed

**AGE**

20 years

**WEIGHT**

9.5

**INTERPRETED BY**

Maggie Machen Lamy,  
DVM, DACVIM  
(Cardiology)

**IMAGING  
PERFORMED BY**

Sang K Han, DVM

**HOSPITAL NAME**

Oso Pet Care Center

**REFERRING VET**

Dr. Han

**INVOICE**

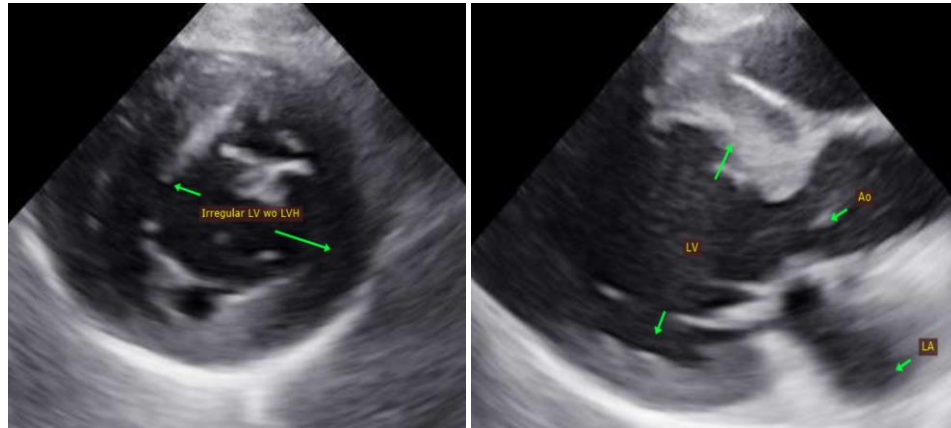
22589

**DATE**

2/15/22

Recommend recheck echocardiogram in 1 year to assess for any progressive issues.

**IMAGES**



The information and recommendations provided are based on the images presented by the referring veterinarian. No evaluation can be communicated regarding pathology that was not visible in the image/video clips provided.

Thank you for this referral. This report was generated using transcription software, and minor dictation errors may be present. If the clinical or image interpretation does not parallel your findings or if I can be of any further assistance, please contact me.

**Maggie Machen Lamy, DVM**  
Diplomate of the American College of Veterinary Internal Medicine (Cardiology)  
info@sonopath.com